



Fact Sheet

From ReproductiveFacts.org



The Patient Education Website of the American Society for Reproductive Medicine

Saline Infusion Sonohysterography (SHG)

What is saline infusion sonohysterography (SHG)?

Saline infusion sonohysterography (SHG or SIS) consists of imaging the uterus and uterine cavity using ultrasonography while sterile saline is instilled into the uterine cavity. The purpose of sonohysterography is to detect abnormalities of the uterus and endometrial (uterine lining) cavity.

Why is SHG performed?

The usual reasons for doing an SHG are abnormal uterine bleeding, infertility, recurrent spontaneous miscarriage, congenital abnormalities of the uterus, preoperative and postoperative evaluation of the uterine cavity, suspected intrauterine adhesions (synechiae or scar tissue), and further evaluation of uterine abnormalities found during routine ultrasonography. SHG should not be performed in women who are pregnant or who are suspected to be pregnant. SHG should also not be performed in women with an active pelvic infection.

How is SHG performed?

SHG is usually performed in the first part of the menstrual cycle after menstruation. The procedure begins with a transvaginal ultrasound examination.

After this is completed, a narrow catheter is placed vaginally through the cervix into the uterine cavity, and the ultrasound examination is continued while sterile saline is instilled into the uterine cavity. The saline solution helps outline the uterine cavity to show abnormalities such as endometrial polyps and intracavitary fibroids.

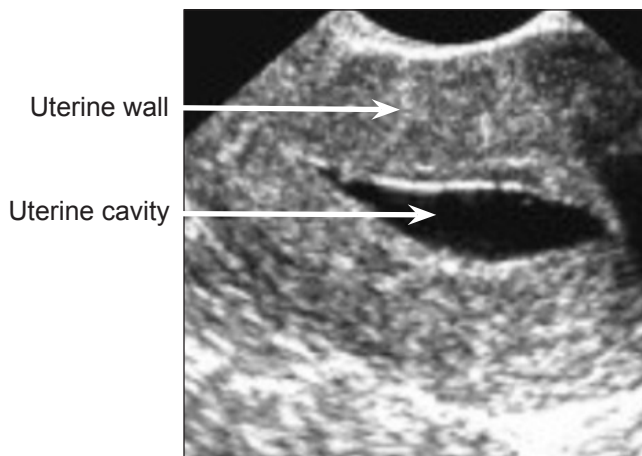
What are the risks and complications?

An SHG is a very safe procedure. It may cause cramping, spotting and vaginal discharge. Some women experience cramping for several hours. The most common serious complication with SHG is pelvic infection; however, this occurs less than 1% of the time and usually occurs when a woman also has a disease of the fallopian tubes. You should call your doctor if you experience pain or fever one or two days after the SHG. Some doctors prescribe pain medication and/or antibiotics before the procedure.

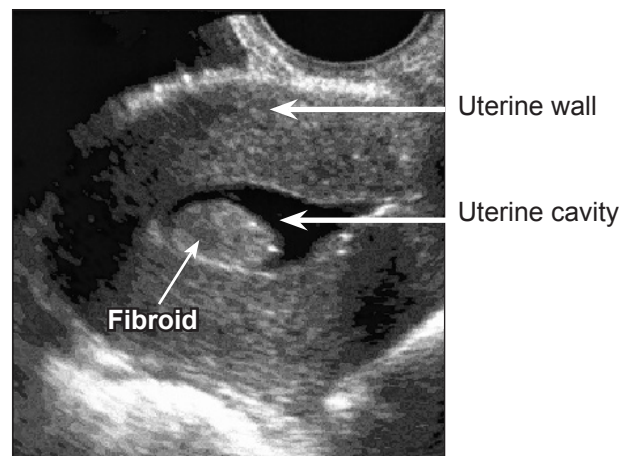
Revised 2012

For more information on this and other reproductive health topics visit www.ReproductiveFacts.org

Normal uterus



Uterus containing fibroid



Images of sonohysterography. The uterine wall and saline in the uterine cavity are seen as black or "empty" space. A fibroid (benign tumor) is seen in the uterine cavity in the image on the right.